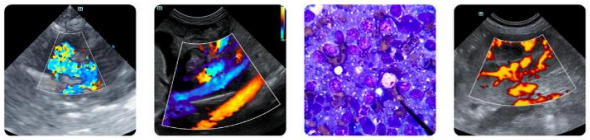

PATIENT
Leia Cuevas

SPECIES
Canine

BREED
Pitbull Mix

SEX
Female Spayed

AGE
8 years

WEIGHT
54.8lbs

INTERPRETED BY
Maggie Machen Lamy, DVM, DACVIM (Cardiology)

IMAGING PERFORMED BY
G. Ferrer, DVM

HOSPITAL NAME
Pulse: Pet Ultrasound Services

REFERRING VET
Dr. Miranda

INVOICE
46686

DATE
2/4/26

PRESENTING CLINICAL SIGNS

History: Recheck echo. Had an emergency Pyometra surgery in 2025. Assess prior to anesthesia for mammary gland mass removal.
-Current medications: Pimobendan 5mg: 1 BID, Spironolactone 50mg BID, Furosemide 40mg BID, Enalapril 10mg BID.
-Pertinent previous echo findings (8/2024 MML): Severe RHE, mild PH; cause unknown.

ECHOCARDIOGRAM FINDINGS

2D, m-mode, color flow and doppler imaging is available. Mild diffuse thickening of mitral valve leaflets with no prolapse into the left atrial lumen. No mitral regurgitation with no left atrial dilation. Septal flattening in systole. Normal LV diameter with adequate myocardial function. The tricuspid valve appears mildly thickened with moderate tricuspid regurgitation. TR Velocity is significantly elevated. Marked right atrial enlargement. Marked right ventricular dilation with mild hypertrophy. The pulmonic and aortic valves are normal in morphology and mobility. Normal pulmonic and aortic outflow velocities with laminar flow. No obvious aortic or pulmonic insufficiency. No pericardial or pleural effusion noted. No obvious cardiac masses. Frequent VPCs are noted throughout the study with periods of bigeminy.

CARDIAC CHART

CANINE CARDIAC PARAMETERS	MR VMAX (m/s)	TR VMAX (m/s)	LA/AO (Boon method)	LA/AO (Heart Base; Swe)	FS (%)	EF (%)	EPSS (cm)
NORMAL PARAMETER	4.5-5.5	<2.7	1.3	<1.6	28-40	40-100	<0.6
PATIENT	NA	4.5	NM	1.3	64	93	0.4
CANINE CARDIAC PARAMETERS	**HR** (BPM)	**AV VMAX** (m/s)	**PV MAX** (m/s)	**BODY WEIGHT** (kg)	**LA** 2D short axis Base view (cm)	**LVIDd** Avg; 2D and m-mode short axis (cm)	**LVIDs** Avg; 2D and m-mode short axis (cm)
NORMAL PARAMETER	50-100	0.7-1.7	0.7-1.6	BELOW	BELOW	BELOW	BELOW
PATIENT	150	0.7	0.7	24.9	2.0	2.9	1.0
*Normal chamber parameters expressed as a mean value (SD)				3	1.27 (5.3)	2.46 (2.46)	1.36 (5.5)
BODY WEIGHT DEPENDENT PARAMETERS				5	1.40 (4.5)	2.74 (5.2)	1.60 (4.7)
***Note: All measurements based upon multi-modal images and methods. An average value is reported.**				10	1.50 (3.8)	3.27 (3.5)	2.06 (3.1)
				15	1.83 (2.0)	3.71 (2.4)	2.43 (2.1)
				20	2.02 (1.9)	4.14 (2.2)	2.80 (2.0)
Adapted from June Boon, Veterinary Echocardiography, 1998				25	2.18 (2.4)	4.48 (2.9)	3.10 (2.5)
Rishniw M and Hollis NE, J Vet Intern Med 2000; 14:429-435				30	2.33 (3.3)	4.83 (3.9)	3.39 (3.4)
Hansson et al, Vet Rad and Ultrasound 2002				35	2.48 (4.3)	5.17 (5.0)	3.69 (4.5)
Bonagura et al. Echocardiography: principles of interpretation, Vet Clin North Am 15:1177, 1995				40	2.62 (5.2)	5.48 (6.1)	3.96 (5.4)
				50	2.88 (7.1)	6.07 (8.3)	4.46 (7.4)

INTERPRETATION OF THE FINDINGS & FURTHER RECOMMENDATIONS

Compared to the prior study, there is progressive right heart enlargement. The pulmonary pressures are more significantly elevated than was previously documented, which is of unknown

PATIENT
Leia Cuevas

SPECIES
Canine

BREED
Pitbull Mix

SEX
Female Spayed

AGE
8 years

WEIGHT
54.8lbs

INTERPRETED BY
Maggie Machen Lamy, DVM, DACVIM (Cardiology)

IMAGING PERFORMED BY
G. Ferrer, DVM

HOSPITAL NAME
Pulse: Pet Ultrasound Services

REFERRING VET
Dr. Miranda

INVOICE
46686

DATE
2/4/26

significance. The left heart remains normal/small in dimension. Finally, VPCs are noted throughout the study with great frequency. An ECG should be obtained for evaluation.

Given these findings, full cardiac support should be continued going forward with addition of Sildenafil. As was discussed in the prior report, this is extremely rare to see. Referral should still be considered for advanced imaging.

Prognosis is poor long-term; however, this patient has done well thus far. Omega fatty acid supplementation and mild salt restriction may be of some long-term benefit. Monitor for development of a cough, labored breathing, exercise intolerance or collapse episodes.

Elective anesthesia is not advised as there is extremely high risk for complication.

PLAN

Consider referral as discussed previously. If declined, continue four medications as prescribed, pending BP assessment. Institute Sildenafil 1-2mg/kg PO q8h.

Monitor renal values and BP every 3-4 months lifelong.

Recommend conservative monitoring with a recheck echocardiogram in 6 months, sooner if any development of clinical signs.

IMAGES

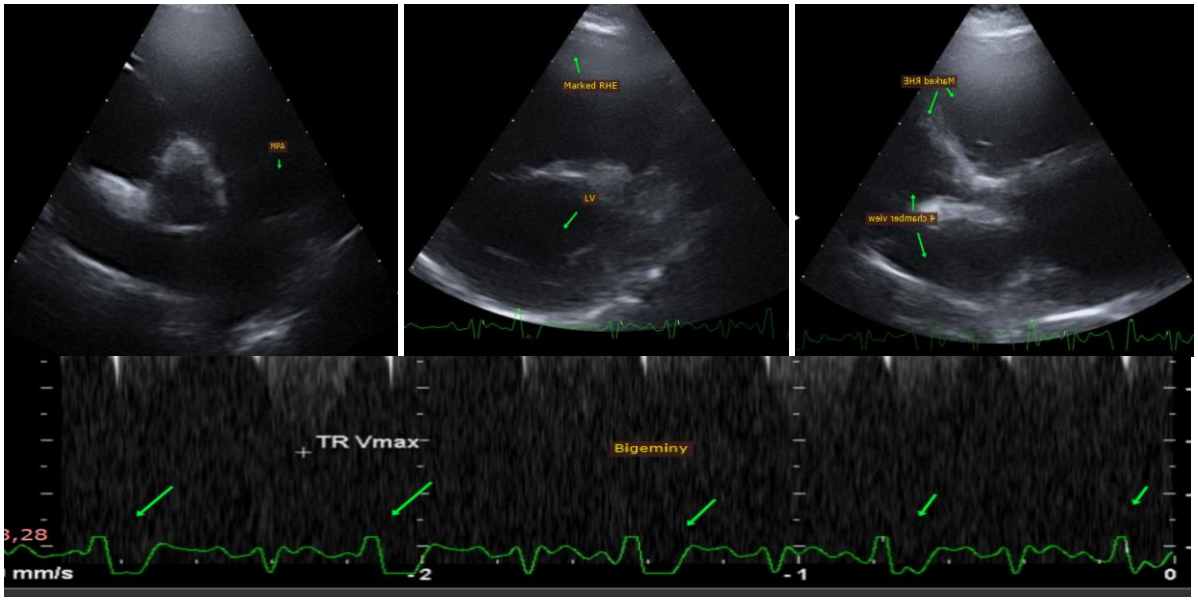

The information and recommendations provided are based on the images presented by the referring veterinarian. No evaluation can be communicated regarding pathology that was not visible in the image/video clips provided.

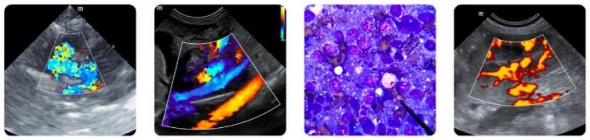

PATIENT

Leia Cuevas

SPECIES

Canine

BREED

Pitbull Mix

SEX

Female Spayed

AGE

8 years

WEIGHT

54.8lbs

INTERPRETED BY

Maggie Machen Lamy, DVM, DACVIM (Cardiology)

IMAGING PERFORMED BY

G. Ferrer, DVM

HOSPITAL NAME

Pulse: Pet Ultrasound Services

REFERRING VET

Dr. Miranda

INVOICE

46686

DATE

2/4/26

Thank you for this referral. This report was generated using transcription software, and minor dictation errors may be present. If the clinical or image interpretation does not parallel your findings or if I can be of any further assistance, please contact me.

Maggie Machen Lamy, DVM
Diplomate of the American College of Veterinary Internal Medicine (Cardiology)
info@sonopath.com